



The Diagnostic Journey of Fahr's Syndrome: A Case Report of Misdiagnosed Multisystem and Neuropsychiatric Symptoms Due to Hypocalcemia Secondary to Hypoparathyroidism

Govind Madhaw^{1*}, Suparna Kumar²

¹Department of Neurology, Center of Neurosciences, Ranchi, Jharkhand, India.

²Department of Psychiatry, Kalinga Institute of Medical Sciences, Bhubaneswar, Odisha, India.

ARTICLE INFO

*Correspondence:

Govind Madhaw
dr.madhaw@gmail.com
Department of
Neurology, Center of
Neurosciences, Ranchi,
Jharkhand, India.

Dates:

Received: 14-07-2024

Accepted: 15-09-2024

Published: 25-10-2024

Keywords:

Depression, Anxiety,
Basal ganglia
calcification,
Hypoparathyroidism,
Fahr disease.

How to Cite:

Madhaw G, Kumar
S. The Diagnostic
Journey of Fahr's
Syndrome: A Case
Report of Misdiagnosed
Multisystem and
Neuropsychiatric
Symptoms Due
to Hypocalcemia
Secondary to
Hypoparathyroidism.
Indian Journal of
Clinical Psychiatry.
2024;4(2): 62-65.

doi: 10.54169/ijocp.v4i02.146

Abstract

Simultaneous psychiatric and neurological manifestations with multisystem involvement often create diagnostic dilemmas and increase the expenditure of undiagnosed cases. It is crucial to rule out reversible medical pathologies before labeling them as primary psychiatric disorders. We present the case of a 50-year-old female complaining of episodic breathlessness with a provisional diagnosis of asthma by a pulmonologist and later on depressive cognition panic attacks pointed towards the diagnosis of moderate depressive episode with somatic symptoms and panic disorder by a psychiatrist. Despite treatment, there was no improvement and new onset focal seizures leading to generalized tonic-clonic seizures evolved. Neuroimaging revealed bilateral diffuse hyperdense parenchymal calcification and metabolic profile showed hypocalcemia secondary to hypoparathyroidism, confirming the diagnosis of Fahr's syndrome. She was prescribed antiepileptics to control seizures and supplemented with high doses of calcium, vitamin D and magnesium. She became asymptomatic within a month. Hence, our case highlights the importance of neuroimaging and metabolic profiles in uncovering hidden aetiologies and formulating individualized treatment strategies.

INTRODUCTION

Somatic symptoms with depressive cognition are frequently encountered by clinicians and at times, it becomes difficult to distinguish between primary psychiatric disorder and underlying medical condition. Patients with involvement of multiorgan systems are at greater risk of misdiagnosis due to its atypical presentation. It increases the disability burden and cost of treatment when we miss a reversible pathology. Thus, it is important to go through a detailed investigation, including neuroimaging and metabolic profile, before labeling as a primary psychiatric disorder.

Here we are going to present a case of a 50 years-old female with episodic shortness of breath, palpitation, anxiety, and depressive symptoms along with

© IJOCp, 2024. Open Access This article is licensed under a Creative Commons Attribution-NonCommercial-ShareAlike 4.0 International (CC BY-NC-SA 4.0) License, which allows users to download and share the article for non-commercial purposes, so long as the article is reproduced in the whole without changes, and the original authorship is acknowledged. If you remix, transform, or build upon the material, you must distribute your contributions under the same license as the original. If your intended use is not permitted by statutory regulation or exceeds the permitted use, you will need to obtain permission directly from the copyright holder. To view a copy of this licence, visit <https://creativecommons.org/licenses/by-nc-sa/4.0/>

pain, paraesthesia and seizure to highlight the diagnostic journey, challenges encountered and the importance of neuroimaging and metabolic workup in formulating the effective treatment strategy.

Case Report

A 50-year-old female with a history of episodic shortness of breath severe enough to wake her up from sleep for past 5 years first visited a pulmonologist. Her pulmonary function test (PFT), computed tomography (CT) thorax and echocardiogram (ECHO) came out to be normal. She was diagnosed with episodic bronchospasm, i.e., asthma and prescribed oral steroids and a combination of inhalational steroids and beta-agonists. Later, she was referred to a psychiatrist as there was no improvement in medications for more than 3 months. The detailed examination revealed each episode lasted for around 30 to 45 minutes, characterized by shortness of breath, choking-like sensation, sweating, palpitation, trembling, and intense fear of dying or losing control over self in the absence of any real-life danger. These episodes were unpredictable and not confined to any particular situation or circumstances. In between the episodes, anticipation of another attack was present. The frequency was around 1 to 2 attacks per week. Furthermore, she also complained of low mood, easy fatigability, decreased interest in pleasurable activities and lack of sleep for 6 to 8 months. On mental state examination, somatic preoccupation, worry regarding her future and ideas of guilt were delineated. A diagnosis of moderate depressive episodes with somatic symptoms and panic disorders was made and she was put on tab escitalopram 10 mg and tab clonazepam 0.5 mg. The pulmonologist also stopped oral steroids and put her on a combination of inhalational steroids and beta-agonists. On follow-up after a month, the guardians reported minimal improvement on medications and also reported two or three episodes of vacant stare during which she failed to respond to external stimuli lasting for 2 to 3 minutes. She was able to continue her previous work and to recognize others immediately after these episodes. She kept silent on asking her about the episodes. There was no history of loss of posture, falling of objects held in hand, or any abnormal movements during these

episodes. These spells were provisionally considered as dissociation with a differential of focal seizure with impaired awareness to be evaluated further. The next time, she came to the emergency Department with an episode of generalized tonic-clonic seizure. The frequency was of around 3 to 4 attacks per day. So, she was started on valproate 1000 mg and later tab levetiracetam 1000 mg was added as a second antiepileptic. She was kept on tab escitalopram 10 mg, clonazepam 0.5 mg, levetiracetam 1000 mg, valproate 1000 mg, a combination of inhalational steroids and beta-agonists. Seizure frequency was reduced to 2 to 3 attacks per week, with ongoing panic attacks in between.

Considering no improvement in episodes of breathlessness, she was re-evaluated thoroughly with a Holter electrocardiogram (ECG) and ECHO by both cardiologist and pulmonologist to rule out PSVT. The reports came out to be normal. On medication, she started having episodic pain and paraesthesia in unilateral upper limbs around the wrist, followed by clinching of fist lasting for minutes with intact awareness of surroundings. In the background of epilepsy disorder, these events were conceptualized as a part of focal seizure. Hence, the dose of levetiracetam was further increased to 1500 mg. The electroencephalogram (EEG) came out to be normal. Bilateral diffuse hyperdense basal ganglia calcification was observed on non-contrast computed tomography NCCT brain (as depicted in Figure 1).

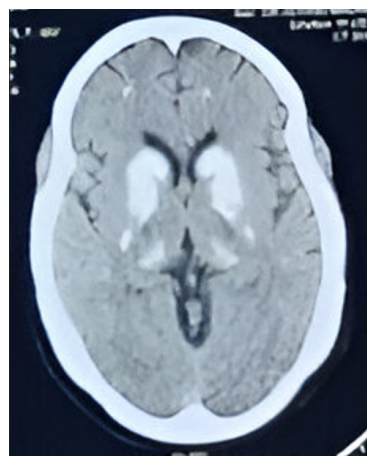


Figure 1: depicts bilateral diffuse hyperdense basal ganglia calcification in non-contrast computed tomography (NCCT) brain of a 50 years old female patient with multisystemic involvement and neuropsychiatric manifestations

This finding opened the arena for metabolic workup, which revealed hypocalcemia secondary to hypoparathyroidism (PTH level- 9.4). All other metabolic profiles were within normal range. Based on her neuroimaging and metabolic profile, the diagnosis of Fahr's syndrome due to hypoparathyroidism was made. The reason behind her varied multiorgan symptoms and non-responsiveness to conventional treatment can be explained with our final diagnosis. The episodes of clinching of fists were nothing but carpopedal spasms, the clinical sign of hypocalcemia. The episodes of severe breathlessness leading to disturbed sleep at night were because by laryngeal spasms caused due to hypocalcemia. Episodes of hypocalcemia precipitated the seizures as well as anxiety spells. Beta-agonists in inhalers further worsened the symptoms of anxiety.

She was started on high-dose calcium and vitamin D supplementation along with magnesium, and to control seizures, carbamazepine 400 mg was added as an antiepileptic. She became asymptomatic within a month with tab carbamazepine 400 mg, high dose calcium, vitamin D and magnesium supplementation. During the maintenance phase, our plan is to look for ionized calcium with the help of arterial blood gas analysis (ABG) during hypocalcemic episodes for further optimization of supplementation. This was a good learning case for psychiatrists, pulmonologists, cardiologists as well as neurologists.

DISCUSSION

Our case report highlights the diagnostic journey of Fahr's syndrome, characterized by chronic hypocalcemia secondary to hypoparathyroidism and bilateral diffuse parenchymal calcification hidden beneath the varied cardiopulmonary and neuro-psychiatric presentation. Laboratory investigations showed that the total blood calcium and free calcium were significantly on the lower side with lower parathyroid hormone (PTH) level and raised phosphorous level. The magnesium was within range, along with a normal bone turnover index. It is important to differentiate between hypoparathyroidism and pseudohypoparathyroidism, characterized by clinical manifestations of hypocalcemia,

hyperphosphatemia, and hyper-PTH due to resistance of target organs like bone and kidney. There was also documentation of physical deformities known as typical Albright hereditary osteodystrophy (AHO) e.g, short stature, obesity, round face, short neck, short finger and even mental retardation in some patients suffering from pseudohypoparathyroidism.¹ No such physical deformity was noticed in our case.

The difference between Fahr's disease and Fahr's Syndrome is based on etiology, prognosis and treatment.² Fahr syndrome occurs always secondary to other causes, the most common being hypoparathyroidism.³ It can also be seen in neuroferritinopathy, Kenny-Caffey syndrome type 1, intrauterine infection (*Toxoplasma gondii*, rubella), tuberous sclerosis complex, brucella infection, etc.⁴ It presents at the age of around 30 to 40 years. On the other hand, Fahr's disease, also known as familial idiopathic basal ganglia calcification, is a rare neurological condition with autosomal dominant or sporadic inheritance patterns accounting for 49% of genetic prevalence and presented around 40 to 60 years of age.⁵ Fahr's disease has also been linked with SLC20A2, PDGFRB, PDGFB, XPR1 and other novel mutations in the myogenic regulating glycosylase gene.⁶

The cause of hypoparathyroidism should be evaluated properly. In our case report, there was no history of neck surgery, the most common cause of hypoparathyroidism.⁷ There was also no prior exposure to radiation. Other causes, like hypocalcemia due to vitamin D deficiency, liver and kidney dysfunction, alkalosis, malnutrition etc were also ruled out. Autoimmune-related hypoparathyroidism or hypofunction of the adrenal cortex and tumor were also ruled out. However, the genetic testing could not be done due to financial limitations and hence, the exact etiology of hypoparathyroidism remained hidden.

Fahr's disease and Fahr's syndrome present with similar clinical signs and symptoms. Neuro-psychiatric symptoms occur in about 40% of cases, ranging from irritability, mood disorders,⁸ cognitive impairment,⁹ dementia,¹⁰ frank psychosis mimicking schizophrenia,¹¹ Parkinsonian features,¹² seizure-related disorders¹³ and so on. A study by Aggarwal et al.¹⁴

found that the neuropsychological dysfunction in idiopathic hypoparathyroidism is linked with the duration of illness, female sex, serum calcium, and calcium-phosphorus product during follow-up but not with intracranial calcifications. The neuropsychiatric manifestation with bilateral symmetrical calcification of the cerebellum, periventricular white matter and basal ganglia pointed towards Fahr's disease.¹⁵ The underlying pathophysiology may be because of deranged calcium/phosphorus transportation and metabolism or alteration of blood brain barrier.¹⁶ Though, basal ganglia calcification could be an incidental finding up to 20% of asymptomatic patients undergoing computed tomography (CT) or magnetic resonance imaging (MRI) scan.⁶

Currently, there is no definitive cure for Fahr disease, whereas Fahr's syndrome showed remarkable improvement with correction of underlying pathology.¹⁷ The treatment of hypoparathyroidism depends on the severity of hypocalcemia, symptomatology and the onset of symptoms. Chronic hypoparathyroidism can usually be treated with oral supplementation of calcium, calcitriol and other active vitamin D analogs in higher doses,¹⁸ adding to the risk of long-term soft tissue calcification. Hence, the replacement therapy with recombinant human PTH is emerging as an innovative treatment to manage chronic hypoparathyroidism.¹⁹

CONCLUSION

This case highlights the need for a thorough workup, including neuroimaging and metabolic profile, to deal with unexplained multisystem involvement along with neuropsychiatric symptoms. It advocates for an integrated care model that prioritizes comprehensive evaluation and collaborative management across medical specialties.

REFERENCES

- Cianferotti L, Brandi ML. Pseudohypoparathyroidism. *Minerva Endocrinol.* 2018 Jun;43(2):156–67.
- Amisha F, Munakomi S. Fahr Syndrome. In: StatPearls [Internet]. Treasure Island (FL): StatPearls Publishing; 2024 [cited 2024 Aug 3]. Available from: <http://www.ncbi.nlm.nih.gov/books/NBK560857/>
- Chen JQ. Fahr's syndrome, intracranial calcification and secondary hypoparathyroidism. *QJM Mon J Assoc Physicians.* 2022 Jul 9;115(7):481–2.
- Zhou YY, Yang Y, Qiu HM. Hypoparathyroidism with Fahr's syndrome: A case report and review of the literature. *World J Clin Cases.* 2019 Nov 6;7(21):3662–70.
- Chhetri B, Gyeltshen D, Letho Z. Bipolar affective disorder in a patient with Fahr's disease: The first recorded case in Bhutan. *SAGE Open Med Case Rep.* 2022 Sep 15;10:2050313X221125324.
- Donzuso G, Mostile G, Nicoletti A, Zappia M. Basal ganglia calcifications (Fahr's syndrome): related conditions and clinical features. *Neurol Sci Off J Ital Neurol Soc Ital Soc Clin Neurophysiol.* 2019 Nov;40(11):2251–63.
- Arruda ACG de, Guerra ACDZ, Pessoa CH, Marquezine GF, Delfino VDA. Hypoparathyroidism and Fahr's syndrome: case series. *J Bras Nefrol.* 2022;44(4):592–6.
- Ishitobi M, Kumashiro N, Nakao K. Clinical features of bipolar disorder with idiopathic basal ganglia calcification: a review of case reports in the literature. *Neurocase.* 2019;25(3–4):145–50.
- Jensen MP, Spasic-Boskovic O, Rowe JB, Galton C, Allinson KSJ. Clinicopathological co-occurrence of Fahr's disease and dementia with Lewy bodies. *Clin Neuropathol.* 2020;39(5):227–31.
- Ghogare AS, Nemade S. Fahr's Syndrome Presenting As Pre-senile Dementia With Behavioral Abnormalities: A Rare Case Report. *Cureus.* 2021 Dec;13(12):e20680.
- Mohapatra S, Satapathy A. A Case of Schizophrenia Like Psychosis Due to Fahr's Disease. *Indian J Psychol Med.* 2016;38(2):155–6.
- Scarano S, Rota V, Tesio L, Perucca L, Robecchi Majnardi A, Caronni A. Balance Impairment in Fahr's Disease: Mixed Signs of Parkinsonism and Cerebellar Disorder. A Case Study. *Front Hum Neurosci.* 2022;16:832170.
- Katwal S, Bhandari S, Ghimire A, Ghimire P. Fahr's syndrome with hypoparathyroidism, thrombocytopenia, and seizure: a rare case report. *Ann Med Surg.* 2023 Aug;85(8):4131–3.
- Aggarwal S, Kailash S, Sagar R, Tripathi M, Sreenivas V, Sharma R, et al. Neuropsychological dysfunction in idiopathic hypoparathyroidism and its relationship with intracranial calcification and serum total calcium. *Eur J Endocrinol.* 2013 Jun 1;168(6):895–903.
- Ooi HW, Er C, Hussain I, Kuthiah N, Meyyur Aravamudan V. Bilateral Basal Ganglia Calcification: Fahr's Disease. *Cureus.* 2019 Jun 1;11(6):e4797.
- DURANTE A, AUDINO N, CRISTIANO M, TANGA M, MARTINO MT, NOSCHESE I, et al. Basal ganglia calcification: a Fahr's disease case report. *Radiol Case Rep.* 2021 Aug 12;16(10):3055–9.
- Subbiah S, Natarajan V, Bhagadurshah RR. Fahr's Disease and Hypoparathyroidism - A Missing Link. *Neurol India.* 2022;70(3):1159–61.
- Marcucci G, Brandi ML. Conventional Treatment of Hypoparathyroidism. *Front Horm Res.* 2019;51:160–4.
- Bilezikian JP. Hypoparathyroidism. *J Clin Endocrinol Metab.* 2020 Jun 1;105(6):1722–36.